

Healing evolution of surgical wound dehiscence in sternotomy

Evolução cicatricial de uma deiscência de ferida operatória em esternotomia

Evolución en la cicatrización de la dehiscencia de una herida operatoria en esternotomía

Adriana Jorge Brandão¹

ORCID: 0000-0002-5539-0152

Verônica Elis Araújo

Rezende¹

ORCID: 0000-0001-9076-3375

Lucilene da Silva Silva¹

ORCID: 0000-0001-9615-5362

Yara Maria Rego Leite¹

ORCID: 0000-0002-4868-2624

Iana Cibelly Moreira de Vasconcelos¹

ORCID: 0000-0003-3049-0445

¹Hospital Universitário da
Universidade Federal do Piauí,
Teresina, Piauí, Brasil.

Corresponding author:
Iana Cibelly Moreira de Vasconcelos
E-mail: ianacibelly.iv@gmail.com

Abstract

Objective: To describe the healing evolution of surgical wound dehiscence in a sternotomy patient during the postoperative period of mitral and aortic valve replacement. **Methods:** A descriptive survey of the case study type, developed in the medical clinic of a University Hospital from the EBSERH network on a patient with surgical wound dehiscence in sternotomy. The data were obtained through direct evaluation of the lesion, photographic assessment and written records in the patient's medical chart from July to September 2021. The study was approved by the Research Ethics Committee of the University Hospital belonging to the Federal University of Piauí (*Hospital Universitário da Universidade Federal do Piauí, HU-UFPI*) (Opinion number: 5,726,375). **Results:** The patient evolved with a reduction in the measurements of the dehiscent lesion area, proliferation of good granulation tissue and approximation of the lesion edges, with use of Negative Pressure Therapy and adequate dressings for each phase of the healing process. **Conclusion:** Knowledge about the wound healing process associated with the use of products and technologies, such as Negative Pressure Therapy, was fundamental in the treatment of surgical wound dehiscence, avoiding a new surgical approach, as well as reducing costs and hospitalization time.

Descriptors: Surgical Wound Dehiscence; Nursing Care; Wound Healing.

What is already known on this?

It is fundamental that nurses are trained to assess wounds and indicate the dressing that best suits each phase of the wound healing process.

What this study adds?

It shows a successful experience in surgical wound dehiscence management, highlighting Nursing care and the use of available technologies such as Negative Pressure Therapy for healing evolution, avoiding a new surgical approach, as well as reducing costs and hospitalization time.



How to cite this article: Brandão AJ, Rezende VEA, Silva LS, Leite YMR, Vasconcelos ICM. Healing evolution of surgical wound dehiscence in sternotomy. Rev. enferm. UFPI. [internet] 2023 [Cited: ano mês abreviado dia]; 12:e4046. DOI: 10.26694/reufpi.v12i1.4046

Resumo

Objetivo: Descrever a evolução cicatricial de uma deiscência de ferida operatória em esternotomia de uma paciente em pós-operatório de troca valvar mitral e aórtica. **Métodos:** Estudo descritivo, do tipo estudo de caso, desenvolvido na clínica médica de um Hospital Universitário da rede EBSEERH, em uma paciente com deiscência de ferida operatória em esternotomia. Os dados foram obtidos por meio da avaliação direta da lesão, avaliação fotográfica e dos registros escritos no prontuário da paciente no período de julho a setembro de 2021. O estudo foi aprovado pelo comitê de ética em pesquisa do Hospital Universitário da Universidade Federal do Piauí - HUUFPI (Número do Parecer: 5.726.375). **Resultados:** A paciente evoluiu com redução das medidas da área da lesão deiscente, proliferação de bom tecido de granulação e aproximação das bordas da lesão, com a utilização da Terapia por Pressão Negativa e coberturas adequadas a cada fase do processo de cicatrização. **Conclusão:** O conhecimento acerca do processo de cicatrização de feridas associado ao uso de produtos e tecnologias, como a Terapia por Pressão Negativa, foram fundamentais no tratamento da deiscência de ferida operatória, evitando uma nova abordagem cirúrgica, bem como reduzindo custos e tempo de internação hospitalar.

Descritores: Deiscência da Ferida Operatória; Cuidados de Enfermagem; Cicatrização.

Resumen

Objetivo: Describir la evolución en la cicatrización de la dehiscencia de una herida operatoria en la esternotomía de una paciente en periodo postoperatorio de cambio de válvula mitral y aórtica. **Métodos:** Investigación descriptiva del tipo estudio de caso, desarrollada en la clínica médica de un Hospital Universitario de la red EBSEERH en una paciente con dehiscencia de herida operatoria debida a esternotomía. Los datos se obtuvieron por medio de la evaluación directa de la lesión, al igual que a través de una evaluación fotográfica y de los registros incluidos en la historia clínica de la paciente entre julio y septiembre de 2021. El estudio fue aprobado por el Comité de Ética en Investigación del Hospital Universitario perteneciente a la Universidad Federal de Piauí (HUUFPI) (Número de Dictamen: 5.726.375). **Resultados:** La paciente evolucionó con reducción en las medidas del área de la lesión deisciente, proliferación de buen tejido de granulación y aproximación de los bordes de la lesión, con utilización de la Terapia por Presión Negativa y vendajes adecuados a cada fase del proceso de cicatrización. **Conclusión:** El conocimiento acerca del proceso de cicatrización de heridas asociado al uso de productos e tecnologías, como ser la Terapia por Presión Negativa, fue fundamental en el tratamiento de dehiscencia de herida operatoria, evitando así una nueva cirugía, al igual que reduciendo los costos y el tiempo de internación.

Descriptores: Dehiscencia de Herida Operatoria; Atención de Enfermería; Cicatrización de Heridas.

INTRODUCTION

The skin is the largest organ of the human body and plays an extremely important role in protecting the organism against the invasion of disease-causing agents and the lesions caused by surgical procedures aimed at repairing pathological processes are among the causes related to skin integrity discontinuity. It is noted that these types of lesions can be further subclassified into incisive (minimal tissue loss) and excisive (removal of skin areas).⁽¹⁾

Among the surgical wounds, those resulting from cardiac surgeries stand out. In this sense, it is emphasized that cardiovascular diseases (CVDs) are the main cause of mortality in the Brazilian population and that their prevalence increases significantly with age, with surgical interventions such as myocardial revascularization and valve replacement correction as the most common and highly complex in all stages.⁽²⁾

In addition to being complex, these interventions require adequate treatment in all operative phases, but the postoperative period of cardiac surgeries is marked by instability of the clinical condition, with plenty particularities, mainly because it is a critical care moment, with the possibility of pulmonary, renal, neurological, hematological, digestive, hydroelectrolytic and infectious complications.⁽³⁾

A number of studies describe that 3.5% of the patients may have infectious complications after clean heart surgeries, such as mediastinitis, endocarditis and sepsis; as well as infections at the saphenous vein removal site, sternal region, thoracic surgical wound, vascular access sites, urinary and gastrointestinal tract. Therefore, it is necessary to early identify the clinical signs that a surgical wound may present in case of possible appearance of dehiscence (partial or total rupture of the fascial layer in the postoperative period), which can be edge ischemia, tissue displacement or tunnel formation.^(3,4)

Highly complex wounds can have major repercussions both the patient and for the health system, ranging from prolonged hospitalization time to increased morbidity and mortality rates and higher costs. Therefore, it is necessary that the approach be multidisciplinary in guiding decision-making and therapeutic actions, which will include the patient's general evaluation, nutritional screening, psychosocial support, physical examination of adjacent and injured skin, and observation of the healing process and its possible complications.⁽⁵⁾

Therefore, the appropriate dressing in cases of surgical wound dehiscence is the one that aims at cleaning the wound, controlling exudate, removing devitalized tissues, filling in dead space, protecting the wound and, above all, providing comfort to the patient and a satisfactory evolution.

Thus, this study is justified because it shows nurses' importance as health professionals trained to assess wounds and indicate the dressing that is best suited to each phase of the wound healing process, based on the authors' successful experience in managing a case of surgical wound dehiscence after cardiac surgery. In this sense, the objective of this study was to describe the healing evolution of a surgical wound dehiscence case in a sternotomy patient during the postoperative period of mitral and aortic valve replacement.

METHODS

The current study reports the case of a patient admitted to the Medical Clinic of a University Hospital in the late postoperative period of mitral and aortic valve replacement, with surgical wound dehiscence and infection in the sternotomy. During the entire hospitalization period, the lesions were monitored and appropriate dressings were used for the healing process and infection control.

Thus, this is a descriptive study of the case study type, developed from July to September 2021 in the Medical Clinic of a University Hospital located in the city of Teresina, PI.

The study sample consisted of a patient in the postoperative period of mitral and aortic valve replacement, diagnosed with infection and surgical wound dehiscence during her sternotomy.

Nurses' role in surgical wound dehiscence management in the patient's sternotomy involved the following: anamnesis and general physical examination; initial evaluation of the lesion by the nurses; discussion of the case between the Stomatherapy Research Group at HU-UFPI and the medical team; wound cleaning (a Polyhexamide Biguanide [PHMB] solution was used for cleaning), applying bandages using dressings according to the nurses' evaluation of the lesion evolution (the dressings used included foam with PHMB, foam with silver, alginate fiber with silver, rayon gauze with petrolatum); subsequent evaluations and monitoring of the healing process through observational analysis of the wound appearance and use of the TIME tool, as well as the photographic records taken and visualization of the patient's electronic medical record.

In this sense, it is worth noting the importance of the Stomatherapy Research Group (*Grupo de Pesquisa em Estomaterapia*, GEPE) at HU-UFPI in the evaluation and determination of adequate actions aiming at the healing of chronic or acute injuries. The group is made up of generalist nurses and stomatherapists from HU-UFPI and assists patients hospitalized with wounds at the institution, as well as at the hospital's Stomatherapy Outpatient Service. In addition to that, it is worth noting the Nursing care model adopted at the hospital, Primary Nursing, which allows clinical nurses to know their patients, have autonomy and, thus, be able to establish an individualized care plan for each patient, which is fundamental for patients with wounds, as the healing process and the evaluation of the results obtained can be better monitored.

The study was approved by the Ethics and Research Committee of the University Hospital belonging to the Federal University of Piauí - HU-UFPI (Opinion number: 5,726,375). The researchers obtained the patient's consent through the Free and Informed Consent Form (FICF), first reading its content to the participant so that she could understand and be aware of her voluntary participation. Subsequently, two copies of the FICF were handed in to the two witnesses indicated by the patient to sign them, as the participant was illiterate, and, after signature of the witnesses, a copy was delivered to the participant.

RESULTS

A summary of the case studied is presented below, highlighting the Nursing care aspects in the dressing choice in each phase of the wound evolution.

Female patient, 40 years old, separated, mother of five children, living in the rural area of the municipality of Miguel Alves, illiterate, Catholic, hospitalized on July 12th, 2021, due to dehiscence and surgical wound infection in her sternotomy, in the late postoperative period of mitral and aortic valve replacement, performed at another health institution on June 8th, 2021.

She had the following health history: systemic arterial hypertension, diabetes *mellitus*, former smoker, dyslipidemia and macromastia. She was continuously using the following medications: sodium warfarin 5 mg once a day, furosemide 40 mg once a day, spironolactone 25 mg once a day, sildenafil 10 mg/ml - 10 ml 8/8h. Grade 2 obesity was identified in the nutritional risk screening. Patient on a prescribed low-sodium and low-glycemic diet, under monitoring by the nutrition team.

During hospitalization, bacteriological collection of secretion from the sternal wound was performed, which was isolated in a *Staphylococcus aureus* culture on July 21st, 2021. She made use of the

following antibiotics: metronidazole (from 07/12/21 to 07/13/21); cefepime (from 7/12/21 to 7/13/21); vancomycin (from 7/13 to 8/16/21); piperacillin + tazobactam (from 7/13/21 to 7/27/21); oxacillin (from 7/27/21 to 8/3/21) and meropenem (from 8/3/21 to 8/16/21). On July 30th, 2021, resuture of the lesion was scheduled; however, it was canceled and then rescheduled but, on August 3rd, 2021, the patient was instructed to maintain care with the dressing (lesion already treated with silver hydrofiber) and the surgical approach was canceled.

On August 3rd, 2021, the patient evolved to clinical decompensation with atrial fibrillation, tremors, desaturation, fever, chills, tachydyspnea and hypotension, with application of metoprolol succinate, amiodarone, norepinephrine, volume replacement and non-invasive oxygen therapy, showing improvement of the condition. 24 hours after the initial procedures, weaning of the vasoactive drugs was performed, continuing with constant hemodynamic surveillance. On August 16th, 2021, after the end of the antibiotic therapy and compensation of the clinical condition, the patient evolved to hospital discharge with outpatient monitoring in the Cardiology and Stomatherapy services.

Lesion evolution

Initially, the lesion was evaluated at admission by a Stomatherapy Nurse, a Nurse attending Graduate Studies in Stomatherapy and a Resident Nurse, cleaning with a Polyhexamide Biguanide (PHMB) solution was established as initial course of action, followed by application of foam with PHMB that was kept in place until July 13th (Figure 1B). In a conversation with the Stomatherapy Research Group at HU-UFPI and with the consent of the medical team, Nursing care planning was initiated based on the lesion appearance.

Figure 1. Surgical wound dehiscence in sternotomy and use of foam with PHMB. Teresina, Piauí, Brazil, 2021.

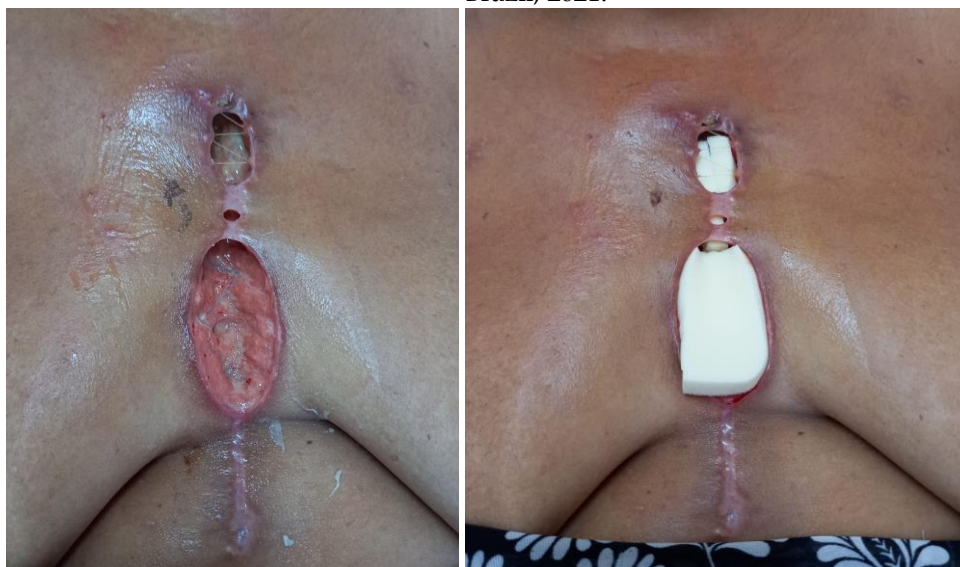


Figure 1A

Figure 1B

Source: The authors.

Figure 1A shows the state of the wound at the time of the first intervention. Appearance of the lesion shows devitalized tissue, dehiscent edges, intense exudate and cavitation. In Figure 1B, foam with PHMB is applied.

It was then decided to use Negative Pressure Therapy associated with foam with silver, which was applied on July 14th (Figure 2B) and kept in place until July 20th.

Figure 2. Surgical wound dehiscence in sternotomy and use of calcium alginate fiber with silver. Teresina, Piauí, Brazil, 2021.

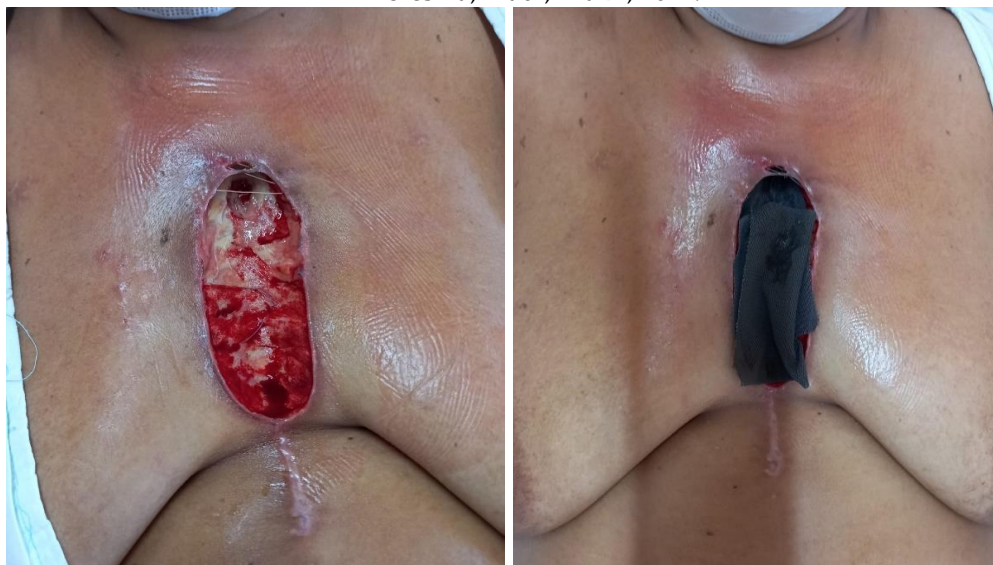


Figure 2A

Figure 2B

Source: The authors.

Figure 2A shows the actual state of the wound after the skin broke in the middle third with total surgical wound dehiscence. Aspect of the lesion shows devitalized tissue, dehiscent edges, intense exudate and cavitation in the upper third. In Figure 2B the lesion is filled with calcium alginate fiber with silver.

On July 20th, when performing dressings, it was decided to fill the lesion with alginate fiber with silver, followed by the application of foam with silver and transparent adhesive film and placement of the Negative Pressure Therapy device, which was kept in place until July 23rd (Figure 3A).

Figure 3. Use of Negative Pressure Therapy in surgical wound dehiscence in sternotomy. Teresina, Piauí, Brazil, 2021.

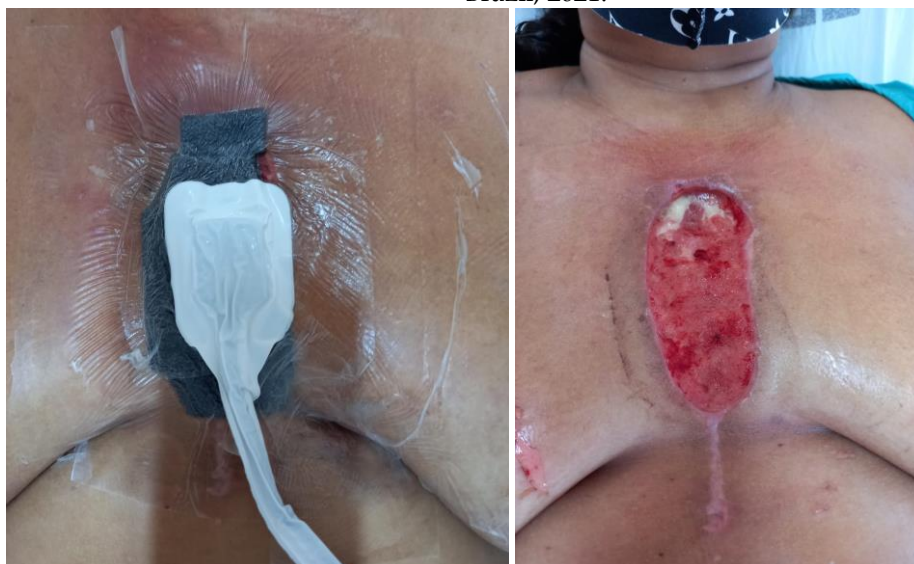

Figure 3A

Figure 3B

Source: The authors.

Figure 3A shows the lesion with the Negative Pressure Therapy device. Figure 3B, from July 23rd, already shows filling of the lesion with good granulation tissue and a significant reduction in devitalized tissue.

Subsequently, on July 23rd, the portable Negative Pressure Therapy system was applied and kept in place for 4 days (Figure 4A). After using Negative Pressure Therapy, wound care was continued with silver hydrofiber.

Figure 4. Use of the portable Negative Pressure Therapy system in surgical wound dehiscence in sternotomy. Teresina, Piauí, Brazil, 2021.

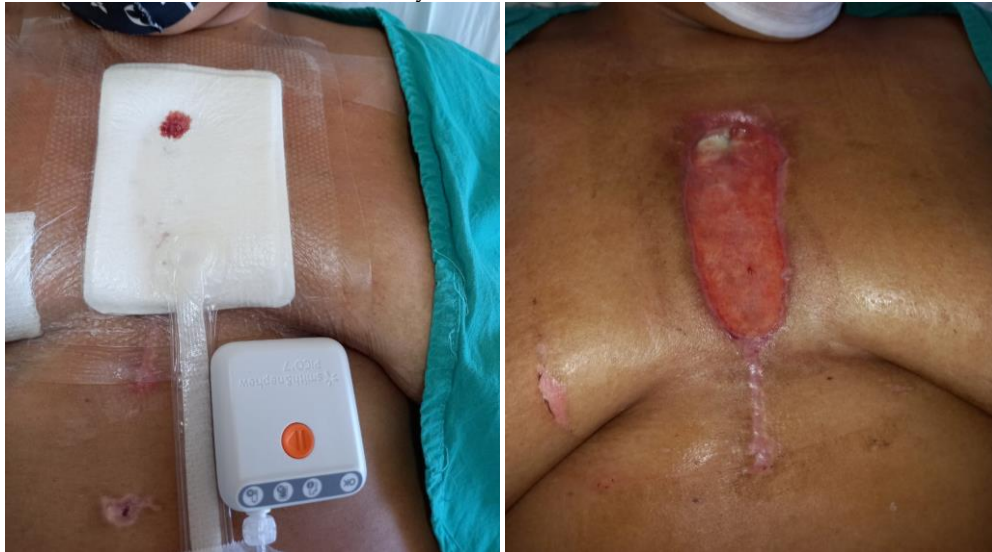

Figure 4A

Figure 4B

Source: The authors.

Figure 4A shows the lesion with the portable Negative Pressure Therapy system. In Figure 4B, on July 28th, the day the portable Negative Pressure Therapy system was removed, we can see approximation of the edges and the lesion bed filled with good granulation tissue.

When almost the entire lesion was filled and the edges converged, on August 11th, it was decided to continue using rayon gauze with petrolatum until hospital discharge, on August 16th. Thus, the patient was monitored throughout her hospitalization in the ward bed, with no need for a surgical approach, a procedure initially proposed by the Cardiology team.

Figure 5. Healing evolution of surgical wound dehiscence in sternotomy. Teresina, Piauí, Brazil, 2021.

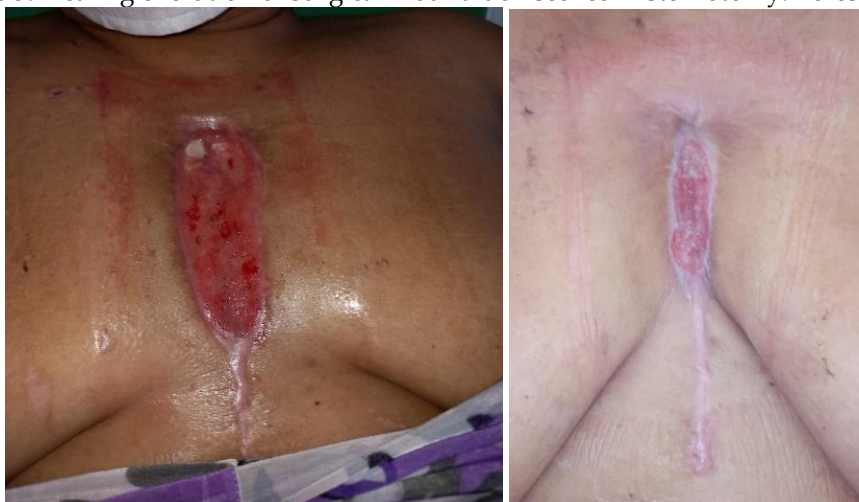

Figure 5A

Figure 5B

Source: The authors.

Figure 5A (August 9th) shows filling of the granulation tissue in the upper third. Figure 5B shows the aspect of the lesion with the patient already undergoing outpatient monitoring, on September 8th.

DISCUSSION

A surgical wound (dehiscence) is defined by the rupture or opening of a previously closed surgical incision. It occurs in 1% to 5% of the surgeries and its development is associated with obesity, infection and suture thread tension.⁽⁶⁾ In relation to cardiac surgeries, median sternotomy is the most used surgical incision and, although rare, complications of deep sternal wounds include sternal dehiscence, deep infections of sternal wounds and mediastinitis.^(7,8)

In the current study, after evaluating and discussing the case among the multiprofessional team members together with the nurses from Stomatherapy Research Group at HU-UFPI, it was decided to use Negative Pressure Therapy associated with special dressings for the treatment of surgical wound dehiscence in the sternotomy of a patient during the postoperative period of cardiac surgery.

Thus, Negative Pressure Therapy (NPT) has emerged over the past two decades as a newer, more effective and safer method for treating sternal wound infections after cardiac surgeries.⁽⁹⁾ It is an active wound care system, non-invasive, occlusive and based on the application of controlled subatmospheric pressure locally applied to the lesion. It consists of a foam or gauze dressing covered with a transparent adhesive film that completely seals the wound, a suction tube connected to this system, and the exudate reservoir that is adapted to a computerized device. Dressings should be exchanged every 48 to 72 hours, as recommended by the manufacturers, as their use for longer periods of time results in foam or gauze saturation, with a consequent reduction in the exudate drainage ability and in treatment effectiveness.⁽⁶⁾

The use of NPT and antibiotics should be the treatment of choice for all deep infections and limited wound dehiscence in the sternal region that do not result in overt sternal instability. With this treatment, a significant number of lesions will heal by second intention without the need for additional reconstructive treatments or for an immediate return to the operating room, with use for prolonged periods of debilitating wet dressings with frequent daily exchanges, actions previously carried out for management of these injuries.⁽⁸⁾

In this study, after using NPT for surgical wound dehiscence during sternotomy, wound care was continued with silver hydrofiber dressings and, subsequently, rayon gauze with petrolatum, observing good wound evolution being, thus not requiring surgical reapproach.

In this sense, in a retrospective study, NPT use was evaluated in patients with superficial and deep sternal wound dehiscence after median sternotomies and it was concluded that these patients benefited from the NPT, as excellent results were achieved such as complete lesion healing and non-recurrence in the follow-up period; therefore, NPT represents a fundamental tool for the treatment of these patients.⁽¹⁰⁾

In another study that compared NPT to other types of dressings for the prevention of sternal wound complications after cardiac surgeries in patients at high risk of complications in the surgical site, it was concluded that the group of patients who received NPT over a closed incision experienced a significantly lower rate of deep sternal complications when compared to groups of patients who received other types of dressings.⁽¹¹⁾

Thus, NPT provides reduced dressing exchanges, patient comfort, shorter hospitalization times, reduced bacterial load and edema and improved skin perfusion, as well as a closed and humid environment for wound healing.⁽¹²⁾ NPT is considered a safe approach; however, complications such as toxic shock syndrome, enteric fistula, hemodynamic instability, bleeding, pain, infection and damage to adjacent tissues have been reported and most of them were attributed to an inadequate technique or inadequate selection of patients.⁽¹³⁾

At hospital discharge, the nurse provided the patient with guidelines on performing and caring for the dressing at her home, and she was also referred to return for monitoring in the UH Stomatherapy Outpatient Service on August 24th. Thus, after hospital discharge, the patient began to be monitored by the HUFI Stomatherapy outpatient service, in conjunction with the hospital's medical team.

Thus, the study contributes by highlighting the importance of nurses as health professionals duly trained to assess and treat lesions, as well as the use of products and technologies for wound treatment, such as Negative Pressure Therapy. However, the study is limited for presenting a single case, requiring further studies with larger populations to show the benefits of these products and technologies in surgical wound dehiscence.

CONCLUSION

Nursing care linked to adequate knowledge about the healing process, as well as the technologies available to cover a wound according to its evolution, is of paramount importance for successful care for

patients with complex wounds. In this sense, knowledge about the use of Negative Pressure Therapy in surgical wound dehiscence can lead to more effective results and with lower costs in the treatment of these lesions. In addition to that, this successful experience can support the elaboration of protocols for dressings with negative pressure in the institution, supporting this therapy, as well as directing decisions to the profile of patients treated at this hospital.

CONTRIBUTIONS

Contributed to the conception or design of the study/research: Brandão AJ, Rezende VEA, Vasconcelos ICM. Contributed to data collection: Brandão AJ, Rezende VEA, Silva LS. Contributed to the analysis and/or interpretation of data: Brandão AJ, Rezende VEA, Leite YMR, Silva LS. Contributed to article writing or critical review: Brandão AJ, Rezende VEA, Leite YMR, Silva LS, Vasconcelos ICM. Final approval of the version to be published: Brandão AJ, Rezende VEA, Leite YMR, Silva LS, Vasconcelos ICM.

ACKNOWLEDGMENTS

To the Stomatherapy Study and Research Group (GEPE) at the University Hospital of Piauí.

REFERENCES

1. Secretaria municipal de saúde de São Paulo. Manual de padronização de curativos. São Paulo: Secretaria municipal de Saúde de São Paulo; 2021.
2. Dordetto PR, Pinto GC, Rosa TCS de C. Pacientes submetidos à cirurgia cardíaca: caracterização sociodemográfica, perfil clínico-epidemiológico e complicações. *Rev Fac Ciênc Méd Sorocab* [Internet]. 2016 [cited 2021 Sep 15];18(3):144-9. Available from: <https://revistas.pucsp.br/index.php/RFCMS/article/view/25868>
3. Soares GMT, Ferreira DCS, Gonçalves MPC, Alves TGS, David FL, Henriques KMC, et al. Prevalência das Principais Complicações pós-operatórias em cirurgias cardíacas. *Rev Bras Cardiologia* [Internet]. 2011 [cited 2021 Sep 25];24(3):139-46. Available from: http://sociedades.cardiol.br/socerj/revista/2011_03/a_2011_v24_n03_01prevalencia.pdf
4. Hospital de clínicas da universidade estadual de Campinas (SP). Manual de processos de trabalho do núcleo de estomaterapia: estomias, feridas e incontinência. Campinas: Hospital de clínicas; 2016.
5. Casteli, CPM, Conceição AP, Ayoub AC. Critérios para realização de curativo em paciente com infecção de órgão/cavidade após cirurgia cardíaca. *Estima* [Internet]. 2017 [cited 2021 Sep 15];15(3):127-31. Available from: <https://www.revistaestima.com.br/index.php/estima/article/view/541>
6. Lima, RVKS, Coltro, PS, Farina, JA. Negative pressure therapy for the treatment of complex wounds. *Rev. Col. Bras. Cir.* [online]. 2017; 44(1):81-93. Doi: <https://doi.org/10.1590/0100-69912017001001>.
7. Schiraldi L, Jabbour G, Centofanti P, Giordano S, Abdelnour E, Gonzalez M, et al. Deep sternal wound infections: Evidence for prevention, treatment, and reconstructive surgery. *Arch Plast Surg*. 2019;46(4):291-302. Doi: 10.5999/aps.2018.01151.
8. Kaul P. Sternal reconstruction after post-sternotomy mediastinitis. *J Cardiothorac Surg*. 2017;12(1):94. Doi: 10.1186/s13019-017-0656-7.
9. Debreceni T, Szerafin T, Galajda Z, Miskolczi S, Péterffy A. A vákuumtámogatott sebkezelés eredményei szívmutétet követő sternotomiás sebfertőzésekben [Results of vacuum-assisted wound closure system in the treatment of sternotomy wound infections following cardiac surgery]. *Magy Seb*. 2008;61Suppl:29-35. Hungarian. Doi: 10.1556/MaSeb.61.2008.Suppl.8.
10. Martino A, Re FD, Falcetta G, Morganti R, Ravenni G, Bortolotti U. Sternal Wound Complications: Results of Routine Use of Negative Pressure Wound Therapy. *Braz J Cardiovasc Surg*. 2020;35(1):50-7. Doi: 10.21470/1678-9741-2019-0242.
11. Brega C, Calvi S, Albertini A. Use of a negative pressure wound therapy system over closed incisions option in preventing post-sternotomy wound complications. *Wound Repair Regen*. 2021;29(5):848-52. Doi: 10.1111/wrr.12914.

12. Agarwal P, Kukrele R, Sharma D. Vacuum assisted closure (VAC)/negative pressure wound therapy (NPWT) for difficult wounds: A review. *J Clin Orthop Trauma*. 2019;10(5):845-8. Doi: 10.1016/j.jcot.2019.06.015.
13. Normandin S, Safran T, Winocour S, Chu CK, Vorstenbosch J, Murphy AM, et al. Negative Pressure Wound Therapy: Mechanism of Action and Clinical Applications. *Semin Plast Surg*. 2021;35(3):164-70. Doi: 10.1055/s-0041-1731792.

Conflicts of interest: No
Submission: 2023/08/03
Revised: 2023/24/04
Accepted: 2023/23/06
Publication: 2023/23/10

Editor in Chief or Scientific: José Wicto Pereira Borges
Associate Editor: Francisca Tereza de Galiza

Authors retain copyright and grant the Revista de Enfermagem da UFPI the right of first publication, with the work simultaneously licensed under the Creative Commons Attribution BY 4.0 License, which allows sharing the work with acknowledgment of authorship and initial publication in this journal.